

EVALUATION OF FACIAL SCAR IMPROVEMENT BY AUTOLOGOUS FAT GRAFTING

Ari Raheem Qader ^a, Kazim A Kakaways ^a, Hawree Abdulsattar Hasan ^a, and Ari Hasan Rashid ^b



Submitted: 30/9/2019; Accepted: 1/12/2020; Published: 21/12/2020

ABSTRACT

Background

Autologous fat grafting widely used in plastic surgery not just for filling the defect, but also for improvement of Scars, this effect of autologous fat may originate from variable contents of adult stem cells and varieties of growth factors in the Lipo - aspirate.

Objectives

To show the effect of autologous fat grafting on improvement of facial scar.

Patients and Methods

Twenty patients with thirty two facial scars, submitted to be treated by autologous fat injection, between April of 2015 - March of 2016 in plastic surgery department and burn Center Hospital in Sulaimani. Preoperative and postoperative follow up include use of patients and observers Scar assessment scale (POSAS) and Photo documentation in first, third and sixth months.

Results

During sixth months of follow up, refinement of scar achieved in all cases, with satisfaction of both patients and observers and all scores of POSAS was significantly improved, for instance; pliability ($p < 0.001$) and stiffness ($p < 0.001$), itching ($p < 0.008$) and so on.

Conclusion

Autologous fat graft is not foreign material, easily achieved; its procedure is minimally invasive. It is very good way to improve scars of face, mainly burn scar. Bigger sample and more follow up time are necessary to delineate the exact effective of autologous fat graft injection on scar.

Keywords: *Facial graft; Fat graf.*

^a Department of Surgery, College of Medicine, University of Sulaimani, Kurdistan Region, Iraq.

^b Board candidate at Kurdistan Board of Medical Specialties, Kurdistan Region, Iraq.

Correspondence: arihrh@yahoo.com

INTRODUCTION

A scar results from the biological process of wound repair in the skin and other tissues of the body and constitutes a natural part of the healing process. It is outcome of mammalian tissue repair which is difficult of being avoided, skin scarring covers a wide spectrum of clinical phenotypes from normal fine lines to abnormal widespread, atrophic, hypertrophic, and keloid Scars and Scar contractures^(1,2).

There are different Modalities used for treatment of Scar include surgical (excision with primary closure, Z-plasty, W-plasty and excision with skin graft), nonsurgical (time, pressure, medication and radiation) and fat graft⁽³⁾.

Adipose tissue is loose connective tissue that serves many purposes both structural and purposes in the body and it is two types white and brown. From histological point of view adipose tissue is primarily composed of adipocyte, preadipocyte, fibroblast, or fat containing cells as well as leukocyte, macrophage, multipotent stem cells⁽⁴⁾.

Biologically, stem cells (SCs) have features of self-renewability that is the capacity not only to divide them rapidly and continuously, but also to create new SCs and progenitors more differentiated than the mother cells⁽⁵⁾.

Stem cells are important source of knowledge for cellular differentiation, molecular processes and tissue homeostasis, but also one of the most putative biological tools to treat degenerative diseases⁽⁶⁾. Adult stem cells (ASCs) are partially committed SCs localized in specific stromal niches. ASCs can be achieved from the mesodermal tissues such as adipose tissue, muscle and BM⁽⁶⁾.

The effective power of improvement of facial scar by autologous fat graft injection may arise from features of adipose tissue-derived stromal cells adipose tissue-derived stromal cells differentiation and other mechanisms such as vasculogenesis, arteriogenesis, angiogenesis, cell preservation, antiapoptosis, anti-inflammation, and others may underlie the potential effectiveness of adipose-derived stem cells as well⁽⁷⁾. It has been described that ASCs regulate vessel density, the granulation process, and collagen thickness and, thus, may improve the cosmetic aspects of the resulting scar.

In spite of that, it has been tried to find out the facts

about newly aspirated fat tissue contains bFGF, IGF, VEGF, and PDGF-B and ASCs the presence of those factors in the various fractions after centrifugation. Which explains their impressive angiogenic capacity and their ability to induce tissue neovascularization.⁽⁸⁾

PATIENTS AND METHOD

This study was based on a prospective clinical evaluation of 20 patients with 32 scars on the face, who were treated using autologous fat graft between April 2015 and May 2016 in burn, plastic and reconstructive surgery in Sulaymaniyah, the patient group included 11 males and 9 females. The patients ages ranged from 13 to 42 years, the most common cause of Scaring was trauma (n=19) followed by postoperative scar (n=1).

Exclusion criterias include:

- 1) Scars of malignant tumor resections of the Face.
- 2) Previous surgical and non-surgical Scar treatment within the past 6 months.

Postoperatively, the patients were followed up at first, third sixths and twelfth months. The postoperative observation period ranged from 6 to 12 months. All patients provided written informed consent for participation.

Surgical procedure

Under general anesthesia, in supine position, Infiltration of abdominal wall was done with a mixture of (6cc of 2% lidocaine, 0.5 cc of adrenalin in a ratio of 1:200,000 and 500cc normal saline 0.9%). Manual fat suction carried out with 1:1 ratio by harvesting cannula which is 2 mm in diameter, 15 cm long with 2 opening ends attach to 10 cc luer lock syringe. With low negative pressure (pulling plunger of syringe up to 2 cc) manual harvesting of fat carried out.

The obtained fat was centrifuged at 3000 rounds per minute for 3 minutes. By this centrifugation, content of syringe separated into 3 components upper part is oil, middle part is purified fat and lower part is RBC and lidocaine, Figure (1).

Later on purified fat transferred to one cc syringes and transplanted subcutaneously into the recipient area with the aid of small diameter blunt cannulas (miniature hole made by small tip needle of syringe to introduce cannula) in tunnel fashion (18 gauge blunt, straight, 9 cm long Coleman cannula) .

Evaluation of Facial Scar Improvement by Autologous Fat Grafting

While for adhesive scar, releasing of tissue scar carried out with aid of V-dissector cannula and thereafter purified fat transferred to recipient area.

Photos and POSAS (Patient Observer Scar Assessment scale) were used, before and after operation. Regarding post operation, patients were followed up in first, third and sixth months by photo documentation and POSAS. Photos were taken in the same room, by the same person and same light. POSAS was used for assessment of Scar before and after operation by both

patients and two independent observers (doctors). Two independent doctors (observer component) for assessment of Scar; paid attention to (Vascularization, Pigmentation, Thickness, Relief, Pliability and Surface area), while patients (patient component) were assessed by asking to (Pain, Itching, Color, Stiffness, Thickness and Irregularity) of scar. As shown in Figure (2, 3) assessment carried out from normal scale; number one (1) scale to worst scales number ten (10). At last follow up period in (sixth month) results of follow up (Photos and POSAS) were presented in this study.

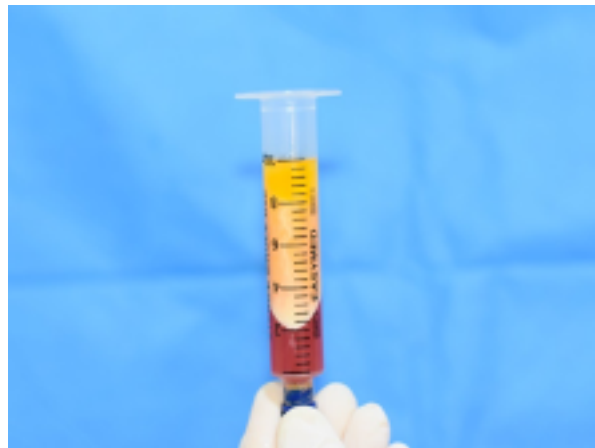

Figure 1 . Note three different layers; oily layer is above; a fatty layer is at middle and lidocaine and RBC at lower layer.

POSAS Observer scale

The Patient and Observer Scar Assessment Scale v2.0 / EN

date of examination:

name of patients:

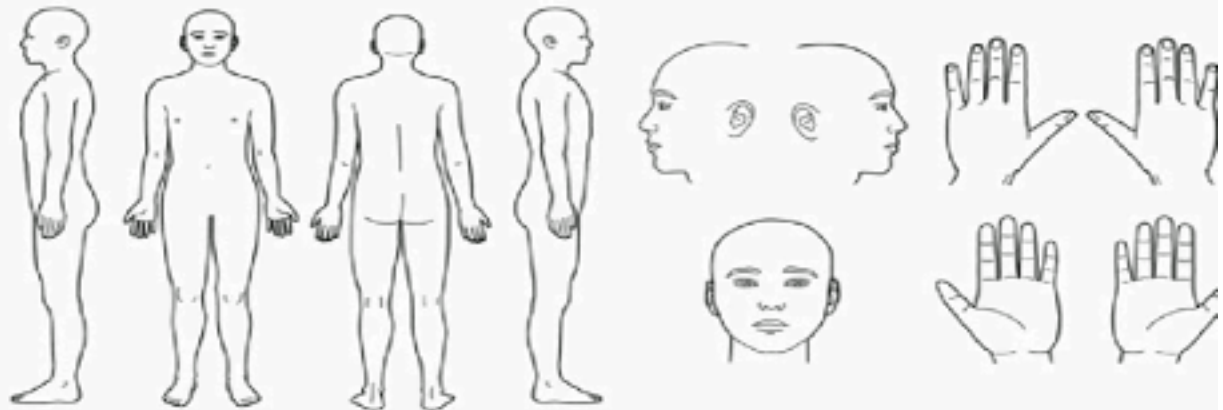
observer:

date of birth:

location:

identification number:

research / study:



	1 = normal skin										worst scar imaginable = 10										
PARAMETER	1	2	3	4	5	6	7	8	9	10	1	2	3	4	5	6	7	8	9	10	CATEGORY
VASCULARITY	<input type="radio"/>	<input type="radio"/>	<input type="radio"/>	<input type="radio"/>	<input type="radio"/>	<input type="radio"/>	<input type="radio"/>	<input type="radio"/>	<input type="radio"/>	<input type="radio"/>	<input type="radio"/>	<input type="radio"/>	<input type="radio"/>	<input type="radio"/>	<input type="radio"/>	<input type="radio"/>	<input type="radio"/>	<input type="radio"/>	<input type="radio"/>	<input type="radio"/>	PALE PINK RED PURPLE MIX
PIGMENTATION	<input type="radio"/>	<input type="radio"/>	<input type="radio"/>	<input type="radio"/>	<input type="radio"/>	<input type="radio"/>	<input type="radio"/>	<input type="radio"/>	<input type="radio"/>	<input type="radio"/>	<input type="radio"/>	<input type="radio"/>	<input type="radio"/>	<input type="radio"/>	<input type="radio"/>	<input type="radio"/>	<input type="radio"/>	<input type="radio"/>	<input type="radio"/>	<input type="radio"/>	HYPO HYPER MIX
THICKNESS	<input type="radio"/>	<input type="radio"/>	<input type="radio"/>	<input type="radio"/>	<input type="radio"/>	<input type="radio"/>	<input type="radio"/>	<input type="radio"/>	<input type="radio"/>	<input type="radio"/>	<input type="radio"/>	<input type="radio"/>	<input type="radio"/>	<input type="radio"/>	<input type="radio"/>	<input type="radio"/>	<input type="radio"/>	<input type="radio"/>	<input type="radio"/>	<input type="radio"/>	THICKER THINNER
RELIEF	<input type="radio"/>	<input type="radio"/>	<input type="radio"/>	<input type="radio"/>	<input type="radio"/>	<input type="radio"/>	<input type="radio"/>	<input type="radio"/>	<input type="radio"/>	<input type="radio"/>	<input type="radio"/>	<input type="radio"/>	<input type="radio"/>	<input type="radio"/>	<input type="radio"/>	<input type="radio"/>	<input type="radio"/>	<input type="radio"/>	<input type="radio"/>	<input type="radio"/>	MORE LESS MIX
PLIABILITY	<input type="radio"/>	<input type="radio"/>	<input type="radio"/>	<input type="radio"/>	<input type="radio"/>	<input type="radio"/>	<input type="radio"/>	<input type="radio"/>	<input type="radio"/>	<input type="radio"/>	<input type="radio"/>	<input type="radio"/>	<input type="radio"/>	<input type="radio"/>	<input type="radio"/>	<input type="radio"/>	<input type="radio"/>	<input type="radio"/>	<input type="radio"/>	<input type="radio"/>	SUPPLE STIFF MIX
SURFACE AREA	<input type="radio"/>	<input type="radio"/>	<input type="radio"/>	<input type="radio"/>	<input type="radio"/>	<input type="radio"/>	<input type="radio"/>	<input type="radio"/>	<input type="radio"/>	<input type="radio"/>	<input type="radio"/>	<input type="radio"/>	<input type="radio"/>	<input type="radio"/>	<input type="radio"/>	<input type="radio"/>	<input type="radio"/>	<input type="radio"/>	<input type="radio"/>	<input type="radio"/>	EXPANSION CONTRACTION MIX
OVERALL OPINION	<input type="radio"/>	<input type="radio"/>	<input type="radio"/>	<input type="radio"/>	<input type="radio"/>	<input type="radio"/>	<input type="radio"/>	<input type="radio"/>	<input type="radio"/>	<input type="radio"/>	<input type="radio"/>	<input type="radio"/>	<input type="radio"/>	<input type="radio"/>	<input type="radio"/>	<input type="radio"/>	<input type="radio"/>	<input type="radio"/>	<input type="radio"/>	<input type="radio"/>	

DEFINITIONS:

- **VASCULARITY** Presence of vessels in scar tissue assessed by the amount of redness, tested by the amount of blood return after blanching with a piece of Flexiglas
- **PIGMENTATION** Brownish coloration of the scar by pigment (melanin); apply Flexiglas to the skin with moderate pressure to eliminate the effect of vascularity
- **THICKNESS** Average distance between the subcuticular-dermal border and the epidermal surface of the scar
- **RELIEF** The extent to which surface irregularities are present (preferably compared with adjacent normal skin)
- **PLIABILITY** Suppleness of the scar tested by wrinkling the scar between the thumb and index finger
- **SURFACE AREA** Surface area of the scar in relation to the original wound area

Figure 2. Patient and Observer Scar Assessment Scale (Observer scale) ⁽⁹⁾.

RESULTS

Twenty patients involved in this prospective study.

General refinement in the quality of the Scars in all cases achieved, In respect of patients satisfaction for their Scar improvement, their Scar complain are generally reduced lastly for pain ($p<0.001$), color($p<0.001$), stiffness($p<0.001$) and irregularity($p<0.001$) .

Regarding Observer Scar score, significant change observed in all questionnaires pliability ($p<0.001$), relief ($p<0.001$) and pigmentation ($p<0.001$), stiffness (<0.001) and thickness ($p<0.001$).

The POSAS results were compared using an unpaired t-test.

The scores of POSAS were improved and observed in all cases.

In general, severe complication of aspirate lipoplasty which including pulmonary embolus, fat embolism syndrome, myocardial infarction, renal shutdown and viscous perforation, fortunately none of these complications happened in our research.

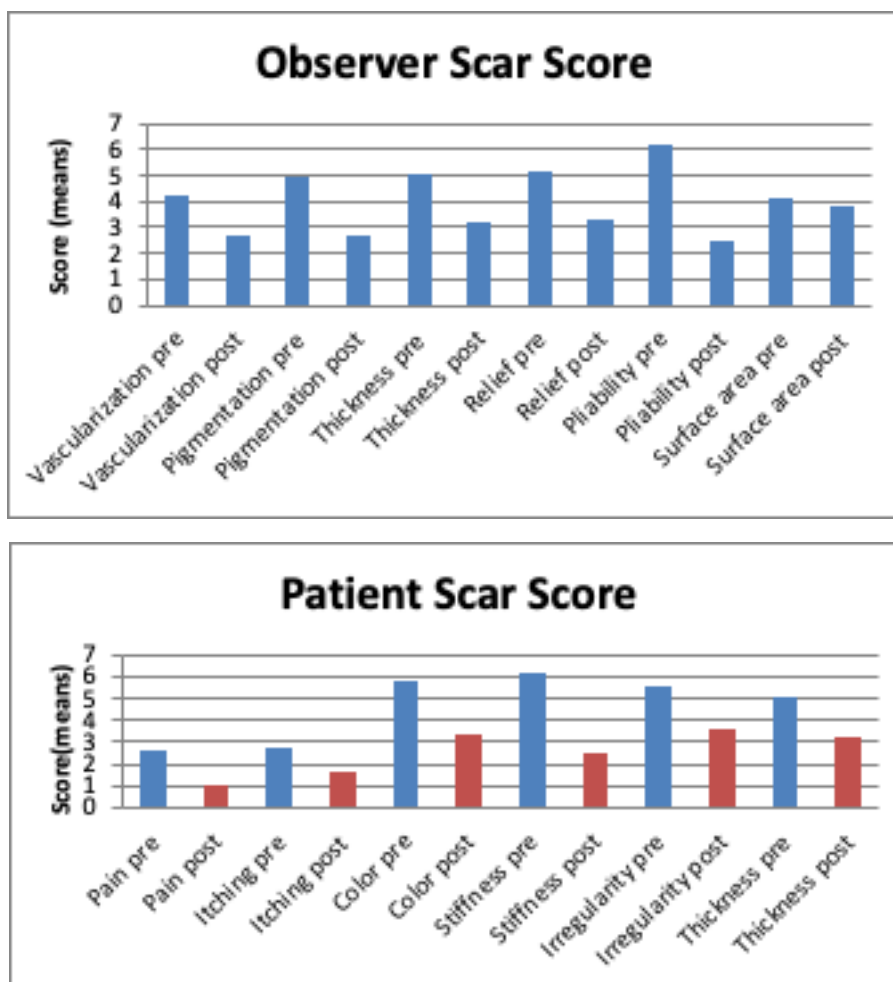


Figure 4. Results of the patient and observer scar assessment scores at the final follow-up ($p< 0.05$).

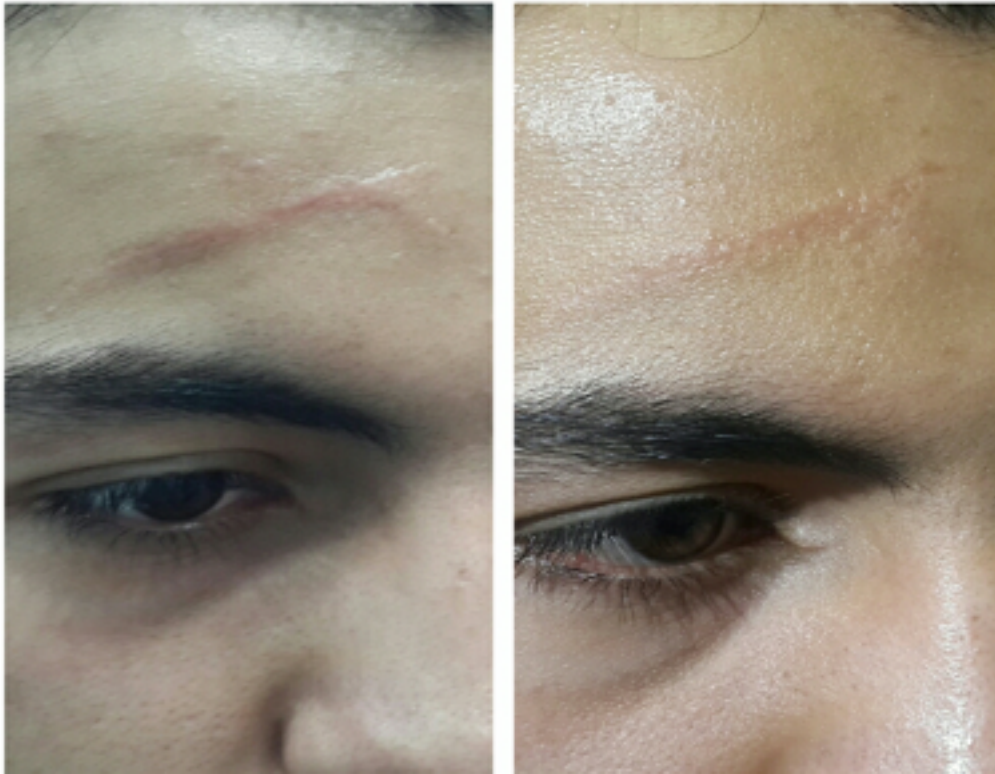

Figure 5 A-B. Pre and postoperative traumatic Scar on forehead.

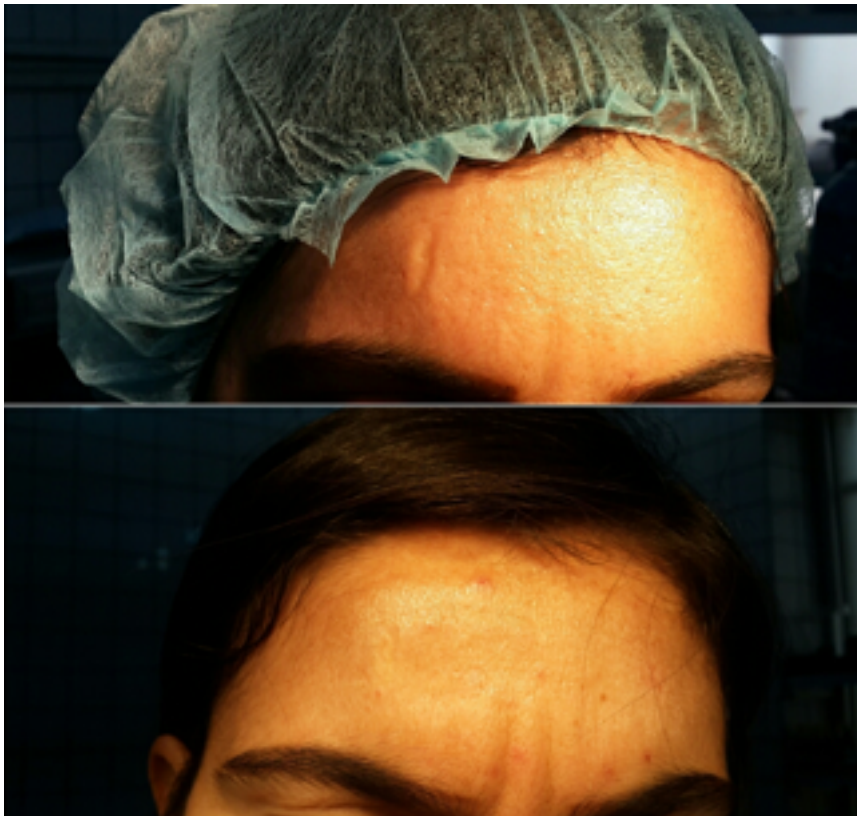

Figure 6 A-B. Pre and postoperative traumatic scar on forehead.

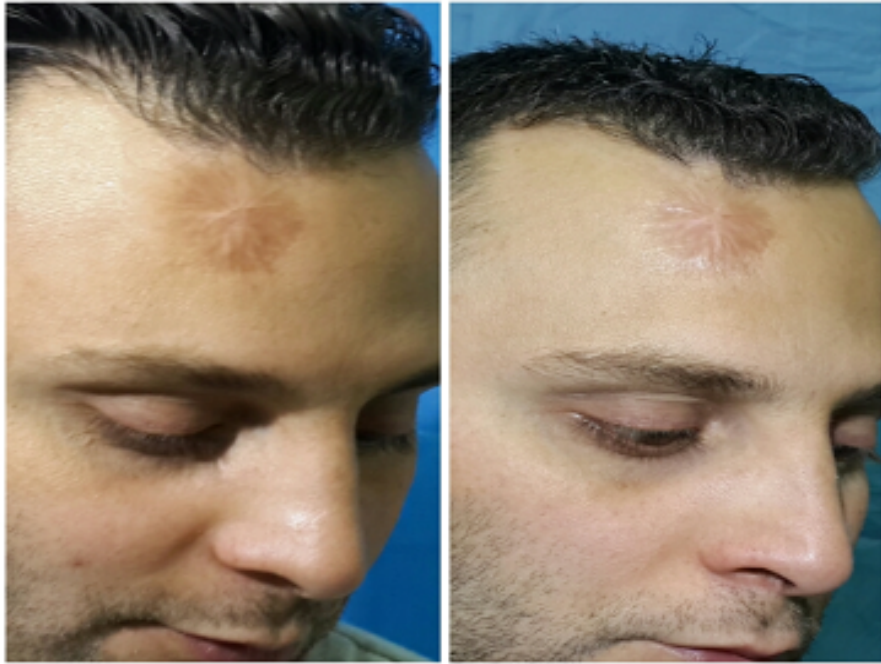

Figure 7 A-B. Pre and postoperative electrical burn Scar on forehead.

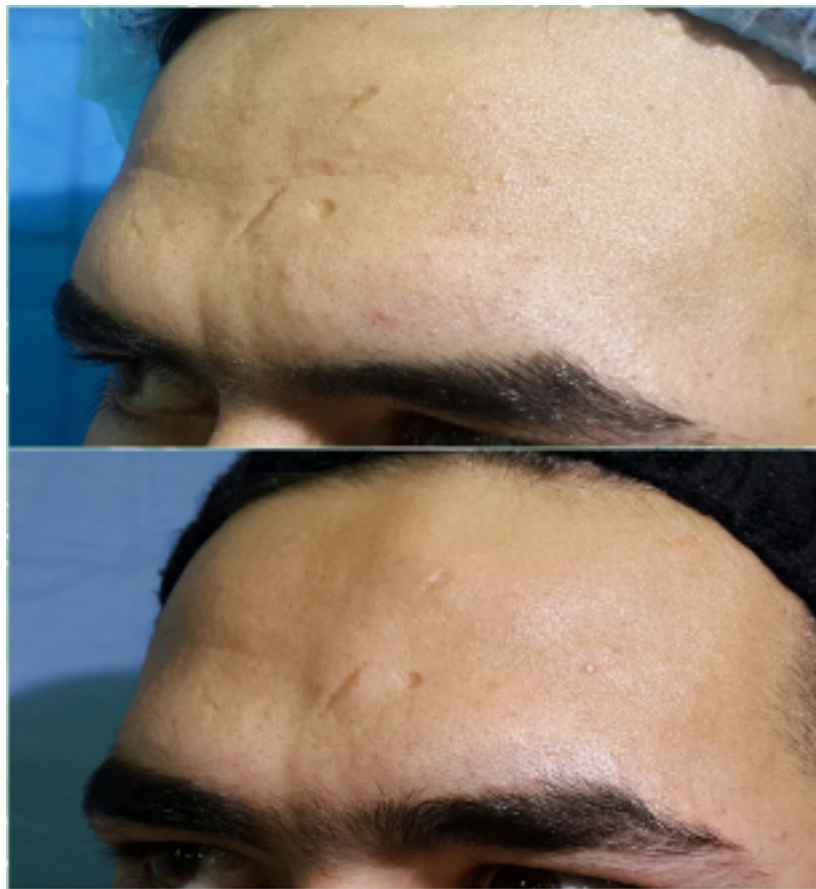

Figure 8 A-B. Pre and postoperative traumatic scar on forehead. with lumpy mass appearance on forehead in picture B .

DISCUSSION

This study demonstrates the potential for performing autologous fat graft injection for scar of face and an extremely good technique for enhancing the general appearance of scars on the face. On the first few weeks after fat graft injection, most patients had mild swelling and bruising on the recipient site, subsequently swelling reduced and bruising disappeared within less than one month.

Refinement in scars of patient in this study observed in three months follow up period, while maximum satisfaction of patients achieved during sixth months follow up period with more happiness of patients for their preoperative scar complaints of stiffness, color, itching, pain and irregularity of scar.

Meanwhile independent observers noted best outcomes of Scar treatment at sixth months of follow up period.

This improvement may originate from the fact that freshly harvested lipoaspirate contains of the growth factors bFGF, IGF-1, VEGF, and PDGF-B in freshly harvested lipoaspirate after centrifugation and ASCs⁽⁸⁾. These findings have similarity with results of other researchers like Pallua et al. In their research showed results of autologous lipofilling on improvement of facial scar appearance and microcirculation that led to a significantly enhanced overall POSAS score in both the patient ($p < 0.0001$) and observer ($p = 0.0025$) groups with three cases overcorrection in 35 patient, meanwhile in this study POSAS score for both patient ($p < 0.001$) and observer ($p < 0.001$) which are also significant with one case of overcorrection in 20 patients⁽⁸⁾.

On the other hand, this study also follows researches of M. Klinger, M. Marazzi, D. Vigo and M. Torre in study of “ Fat Injection for Cases of Severe Burn Outcomes: A New Perspective of Scar Remodeling and Reduction, which demonstrated their results in sixth month follow up period, The clinical appearance and subjective patient feelings suggested considerable improvement in the mimic features, skin texture, softness, thickness, and elasticity was observed⁽¹⁰⁾.

These results are also going with obtained findings of Mazzola et al., who newly explained their results about improvement of facial burn Scar with autologous fat injections in both aspects of functional and aesthetic view. They discussed repeated autologous fat injection (usually 2-3 sessions at 4 month interval) can lead to

more refinement and more effective for skin texture, scar quality, color, mobility of fibrotic tissue and skin graft adhesion. While in our study just one session carried out and all refinement mentioned observed⁽¹¹⁾.

Sydeny R. Coleman stated in (Structural Fat Grafting: More Than a Permanent Filler) that fat can improve the quality of aged and Scarred skin and heal radiation damage and chronic ulcers. Observation over time demonstrates more than just filling of the Scars; this is observed in cases of our study. Sydney R. Coleman also stated; there appears to be remodeling of the Scar over time to the point that an obvious Scar can become imperceptible⁽¹²⁾.

Regina khater and Pepe Atanassova investigated their outcomes of autologous fat injection in both reconstructive and aesthetic points of view for determining effect of anatomical placement of fat graft on clinical outcome (Khater, 2010). They made a comparison of results after fat grafting in head and neck region, other anatomical regions of body; they noted more favorable results with statistical significance ($p < 0,05$) in the head and neck region. They returned their results to higher blood supply of head and neck. In their research, they also compared the results assessments after autologous fat transplantation for esthetic and reconstructive indications and found considerably better results in the esthetic group ($p < 0,0001$). Similarly regarding our recipient site of fat injection face is contemplated and significant result of improvement in Scar qualities in all views acquired⁽¹³⁾.

Pierre G. Vico, Axel Delange, and Axel De Vooght noted in Clinical Study of “Autologous Fat Transfer: An Aesthetic and Functional Refinement for Parotidectomy” showed, their results have a very good survival of the fat graft, which made good or very good reproducible long term effects on the clinical (aesthetic as well as functional aspects) and on the radiological points of view, even if there is a partial resorption of the fat graft. In our study also stated some resorption of fat happened and clinical refinement even gained in patients scar⁽¹⁴⁾.

Ali Modarresi et al, recommended combination of platelet rich plasma (PRP) for all fat grafting and proposed better fat graft survival and less bruising and graft inflammation occurred. while in our research we used purified fat graft alone without case of infection Regarding resorption and viability of fat graft in this study; Viability of purified fat graft typically ranging

from 60% to 70% of what has been grafted in tunnel fashion. Even with notably areas of face that have the least motion have the best survival outcomes ⁽¹⁵⁾.

From explanation of Francesco Arcuri et al, in role of fat grafting in the treatment of posttraumatic maxillofacial deformities suggested one case from nineteen cases had superficial abdominal hematoma and needed percutaneous surgical drainage at 2 days postoperatively. While in this study even in 20 patients this complication had not been reported ⁽¹⁶⁾.

Attempts at slight overcorrection has been carried out for scar, because during placement of fat graft, fat graft has no blood vessel communication with surrounding vessel and only parts of graft with direct contact of surrounding tissue take nutrient and viable tissue was observed in peripheral zone approximately 1.5 ± 0.5 mm from the edge of the graft ⁽¹⁷⁾.

In this study one case has overcorrection of fat graft on forehead in which he may need treatment after sixth month with suctioning of fat by small liposuction cannula ⁽¹⁸⁾. Concern to assessment of preoperative and postoperative scar, POSAS has been chosen, because it is reliable, feasible and able to be accepted, both patients and observers have own right to participate in assessment of scar ^(9, 19).

Related to scars of malignant excision of face, autologous fat graft has not carried out, because chance of recurrence of tumor is in debate ⁽²⁰⁾. So the future of life in concern of operation may change to minimal and non-invasive therapy or it may replace by healing of body by itself and the risks associated with fat grafting procedures may actually be lower than for other types of surgery for surgical treatment of scar and the need for sterile technique should be emphasized ^(20, 21).

In conclusion, treatment of scar by autologous fat injection is less invasive procedure of surgery, easily achieved, unlimited availability, no additional scarring, It has role in improvement of functional and esthetic point of view, ultimately further studies and bigger samples are needed to determine its exact mechanism and effect respectively.

We recommended using autologous fat graft for facial scars to improve appearance and decrease visibility as it's safe and less costly with good outcome.

REFERENCES

1. Trivedi N, Vhankade R. Minimizing Facial and Periocular Scars. Gujarat Ujarat Medical Journal. 2012; 67(2):104-9.
2. Trudged EE, Levi B, Donelan MB. Biology and Principles of Scar Management and Burn Reconstruction. Surg Clin North Am. 2014; 94(4):793-815.
3. Wolfram D, Tzankov A, Pülzl P, Piza-Katzer H. Hypertrophic scars and keloids--a review of their pathophysiology, risk factors, and therapeutic management. Dermatol Surg. 2009; 35: 171-181.
4. Murano I, Zingaretti C. M.. The adipose organ of Sv129 mice contains a prevalence of brown adipocytes and shows plasticity after cold exposure. Adipocytes.2005; 1: 121-130.
5. Bezie M, Mesfin Y, Biyazen H. Stem Cell Biology and its Role in Regenerative Medicine: A Concept Shaping the Future of Medicine. J Regen Med .2016;vol5(1):1-8
6. Lodi D, Iannitti T, Palmieri B. Stem cells in clinical practice: applications and warnings. J Exp Clin Cancer Res 2011; 30(1): 9.
7. M. W. Blanton, I. Hadad, B. H. Johnstone et al., "Adipose stromal cells and platelet-rich plasma therapies synergistically increase revascularization during wound healing," Plastic and Reconstructive Surgery.2009; vol. 123(2): 565-645.
8. Pallua N, Baroncini A, Alharbi Z, Stromps J. Improvement of facial scar appearance and microcirculation by autologous lipofilling. J Plast Reconstr Aesthet Surg. 2014;67(8):1033-1037
9. van der Wal MB1, Tuinebreijer WE, Bloemen MC, Verhaegen PD, Middelkoop E, van Zuijlen PP. Rasch analysis of the Patient and Observer Scar Assessment Scale (POSAS) in burn scars. Qual Life Res. 2012 Feb;21:13-23.
10. Klinger M, Marazzi M, Vigo D, Torre M. Fat injection for cases of severe burn outcomes: a new perspective of scar remodeling and reduction. Aesthetic Plast Surg. 2008; 32: 465-469.
11. Mazzola, R.; Cantarella, G.; Torretta, S.; Sbarbati, A.; Lazzari, L.; Pignataro, L. Autologous fat injection to face and neck: From soft tissue augmentation to regenerative medicine. Acta Otorhinolaryngol. Ital. 2011, 31, 59-69
12. Sydney R. Coleman. Structural Fat Grafting: More Than a Permanent Filler. PRSJ.2006; 118(3S):108S-120S.

Evaluation of Facial Scar Improvement by Autologous Fat Grafting

13. Khater R, Atanassov P. Autologous Fat Grafting -Factors of Influence on the Therapeutic Results. *Current Concepts in Plastic Surgery*. 2010; 183-210.
14. Vico PG, Delange A, Vooght AD. Autologous Fat Transfer: An Aesthetic and Functional Refinement for Parotidectomy. *Surgery Research and Practice*. 2014; 2014 Jan 8:1-6.
15. Modarressi A. Platelet Rich Plasma (PRP) Improves Fat Grafting. PRP in fat grafts. *World J Plast Surg*. 2013 Jan;2(1):6-13 .
16. Arcuri F, Brucoli M, Baragiotta N, Stellin L, Giarda M, Benech A. The Role of Fat Grafting in the Treatment of Posttraumatic Maxillofacial Deformities. *Craniofacial Trauma and Reconstruction*. 2013; 6(2):121-126.
17. Carpaneda CA, Ribeiro MT. Study of the Histologic Alterations and Viability of the Adipose Graft in Humans. *Aesth Plast Surg*. 1993 June; 17:43-47.
18. Coleman RS. Lower Lid Deformity Secondary to Autogenous Fat Transfer: A Cautionary Tale. *Aesthetic Plastic Surgery*. 2008 January; 32:415-7.
19. Draaijers LJ, Tempelman FRH, Botman YAM, Tuinebreijer WE, Middelkoop E, Robert W, et al. The Patient and Observer Scar Assessment Scale: A Reliable and Feasible Tool for Scar Evaluation. *PRSJ*. 2003; 113(7):1960-5.
20. Vallejo A, Urban C, Zucca-Matthes G, Rietjens M. Is there enough evidence to use lipofilling in breast cancer reconstruction? *Plast Reconstr Surg*. 2013; 132(4):689-91.
21. Hammer-Hansen N, Akram J, Damsgaard TE. The Versatility of Autologous Fat Transplantation in Correction of Facial Deformities: A Single-Center Experience. *Plastic Surgery International*. 2015 Mar:1-6.